



ANIMAL DENTISTRY
REFERRAL SERVICES



**GOOD DENTAL HEALTH ISN'T
JUST IMPORTANT FOR HUMANS
TO MAINTAIN.**

DENTAL CONDITIONS ARE PAINFUL

Almost every condition listed
within is *painful to the pet.*

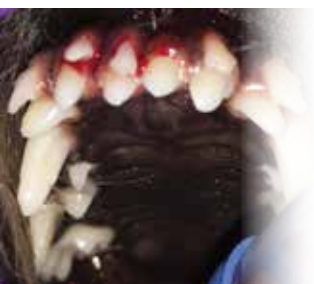Baby Teeth Problems
Painful Bite
Abnormal Bite
TMJ Problems
Broken Tooth
Open Root Tip
Tip Fracture
Avulsed Tooth
Discolored Tooth
Full Metal Crowns
Crown Fractures
Jaw Fractures
Cleft Lip/Palate
Cavities in Dogs
Tooth Resorption
Stomatitis
Extractions
Dentigerous Cysts
Enamel Defects
Tissue Regeneration
Oral Nasal Fistulas
Salivary Gland Problems
Gingival Hyperplasia
Oral Tumors

Most owners will not notice outward pain but it has been proven that ***pets have the same pain as people.*** Do they not know they can get benefit by showing this pain to their owners? Is it a survival of the fittest mechanism?

The good news is that we can find these conditions that an average of 70% of patients have by using detailed imaging under anesthesia.

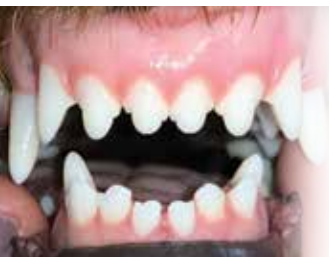When treated, it is known that pets act younger and more playful, an outcome that is a surprise to many owners as the previous pain was not recognized.

***Let's work together to stop oral pain
and save 8 structural teeth in every patient.***



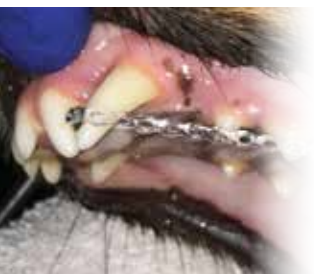BABY TEETH PROBLEMS

Baby teeth naturally are shed as the adult teeth erupt. There are times that although the adult tooth comes in, the baby tooth stays. Two teeth in the same spot in any dog or cat 25 weeks of age or older requires correction. The roots of baby teeth are two to four times the length of the crown, thus usually require surgical extraction to ensure each root is removed fully. Eye and nasal issues later in life have been known to result from retained roots.



PAINFUL BITE RESULTING IN NEED TO MOVE TEETH

Sometimes we see baby lower canine teeth located too far towards the middle of the lower jaw. These sharp needle-like teeth often poke into the roof of the mouth delaying appropriate jaw growth. Any time the lower canines (adult or baby) contact the roof of the mouth, this needs to be corrected. We can use temporary acrylic appliances molded to the teeth to help the teeth to move.



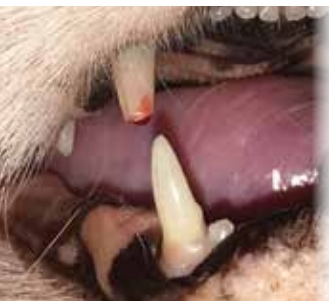ABNORMAL BITE OR LANCED CANINE TEETH NEEDING PET ORTHODONTICS

Yes, we can do braces in pets! Braces are done not for cosmetic reasons but to treat or prevent subsequent pain or infection. One of the most common conditions to use braces are lanced canines—cases in which the tooth is pointing forward instead of down. Correction with orthodontics takes 3 weeks to 3 months depending on the amount of movement and the pet age. Pets tolerate the brackets and elastics very well.



TMJ PROBLEMS

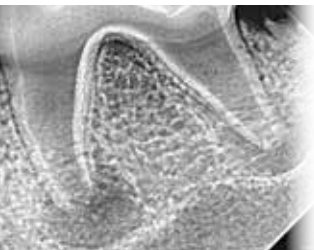
Pets that have problems opening and closing the mouth, or a clicking sound is heard may have temporal mandibular joint (TMJ) problems. Drooling or eating changes can be the only signs owners notice. Surprisingly many pets are good about eating even when they have pain. One or more types of imaging of the TMJ is needed. Depending on the findings, a surgical treatment or orthodontic elastics may be part of the therapy to recovery.



BROKEN TEETH

Chewing hard objects such as bones, antlers, hooves, etc... is the most common reason for tooth breakage. When the pulp is involved through crown or tooth root fracture, the only choices are extraction or root canal therapy (endodontics).

While dogs have 42 teeth and cats have 30, only 8-10 of these teeth are needed for function. We wish to save these teeth through endodontics. This retains structure and function but the tooth is no longer living nor painful.



OPEN ROOT TIP

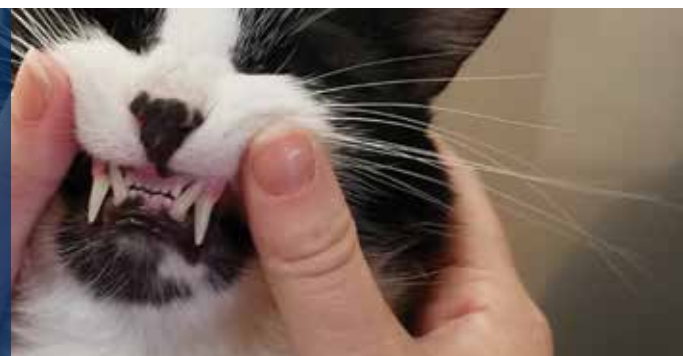In some cases of trauma, the problem occurred while the tooth was still developing the tip of the root (apex). Other times disease of the tooth can dissolve the apex. These teeth still can be saved even with apical disease. They require a non-standard root canal therapy, best termed apexification that is performed over 2-4 separate anesthetic events to result in a structural and functional tooth without disease.



VERY RECENT TIP FRACTURE

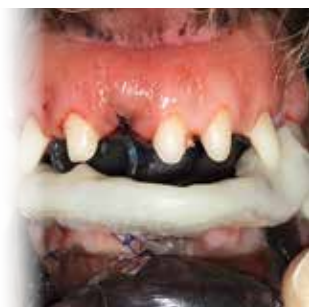Sometimes a tooth will contact an object often during play and the time of tooth fracture will be known. If a tooth fracture is less than 48 hrs old on a dog older than 18 months, or less than 7 days old on a dog younger than 18 months, a 'mini root canal therapy' known as vital pulp therapy (VPT) may be performed. This preserves the vitality, structure, and function of the tooth and just makes it a bit shorter.

Our feline and canine companions are susceptible to many of the same dental ailments as we are.



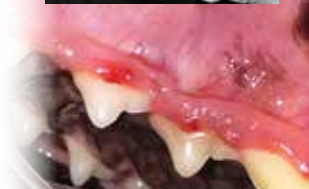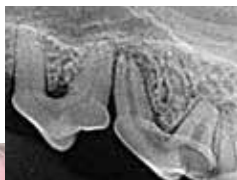
AVULSED TOOTH

There are cases of trauma in which the tooth is 'knocked out' or avulsed without breakage of the tooth root. These teeth need to be put into a glass of milk and can be reimplanted and splinted within 24 hrs. The blood supply to this tooth became disrupted so the pulp dies, but a follow up root canal procedure one week later results in a structural and functional tooth without pain. In some cases, there is not enough bone nor can bone augmentation be sufficient due to surrounding disease, but for many cases, avulsed teeth can be saved.



DISCOLORED TEETH

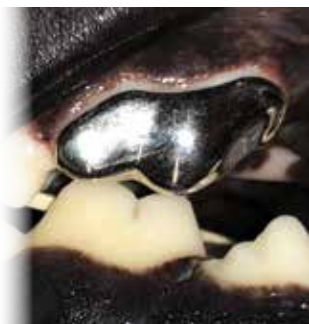Pink, purple, grey or any discolored tooth is dead or dying. 92% of discolored teeth are necrotic while only 42% have radiographic (x-ray) signs. A discolored tooth starts as a painful process to an injury, often goes quiescent, then becomes painful again. Discolored teeth need root canal therapy or extraction as they are or soon will become painful.



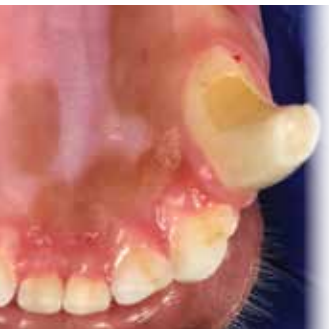CROWNS

Any time a tooth is damaged, structure is lost. If there is reason to believe impact will keep recurring on this tooth (such as chewing hard objects), a crown should be considered. Some reasons for full metal titanium alloy crowns:

- Root canal therapy access sites can weaken the tooth.
- An uncomplicated crown fracture may become complicated with further chewing.
- Teeth with root canal therapy can be more likely to fail without crowns.
- These crowns return the tooth to full strength or stronger than original.

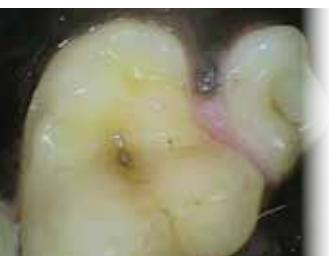

Though dogs have 42 teeth and cats have 30, there are 8 strategic teeth we want to save in each pet: the canines and carnassials.



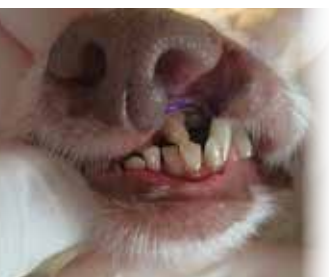UNCOMPLICATED CROWN FRACTURES

Sometimes a tooth will break and the pet will get lucky that the break did not expose the pulp (internal tissue of the tooth = blood and nerves). This results in exposed dentin. Dentin is porous (like lava rock). Saliva and bacteria infect the pulp through the dentinal tubules. If the radiographs (x-rays) show the tooth is not yet affected, a bonded sealant can be applied to seal the tubules stopping the problem. Six months later, follow-up radiographs are needed to verify early infection had not already started unseen and monitor success.



CAVITIES IN DOGS?

While not common, dogs can get true cavities just like people! These are most likely to happen in the upper molar teeth that are shaped more similar to human molars. Catching these soft pits early allows special restorative materials to be placed to correct the problem before it progresses into the pulp requiring root canal therapy or extraction.



CLEFT LIP, CLEFT PALATE

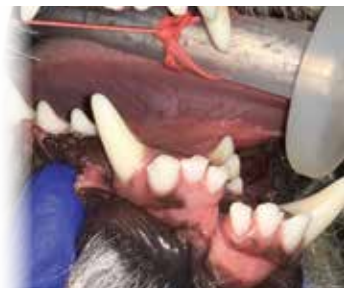During embryonic development a defect can occur causing clefts/openings in the nose, lip, and/or palate. This allows food and fluid from the mouth to enter the nasal passages causing issues. Special surgical techniques are used to close the defects, as there is often insufficient tissue to close in standard surgical fashion. These cases may sometimes require multiple surgeries to correct the problem but the outcome usually makes great improvement in the life of the pet.

Studies show at least half of patients coming into a veterinary office have a hidden painful problem in the mouth.



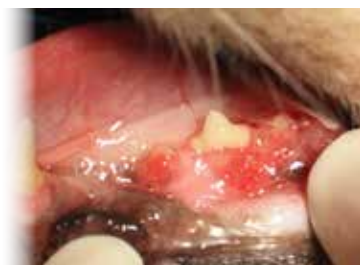JAW FRACTURES

Numerous locations and angles of oral fractures can occur. In patient long bones, veterinarians are taught to correct these with screws and plates. We should not treat the mouth as a long bone, as screws will enter the tooth roots devitalizing them and creating more problems that were originally there. All jaw fracture cases should see a veterinary dentist so that the repair can be through non-invasive methods, correcting the fracture and saving teeth.



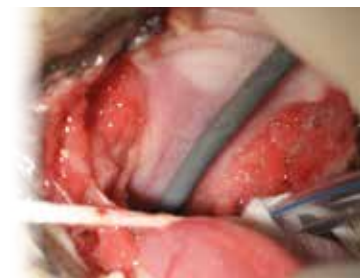TOOTH RESORPTION

70% of cats get tooth resorption. These are often called kitty cavities but are unrelated to lack of brushing. Tooth resorption (TR) occurs as the body attacks its own teeth and 'dissolves' them. Because of the increased incidence of tooth resorption when inflammation is present, when you treat TR through extraction of teeth, you slow the recurrence.

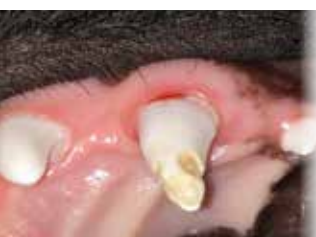
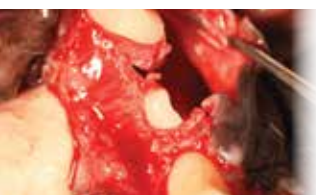
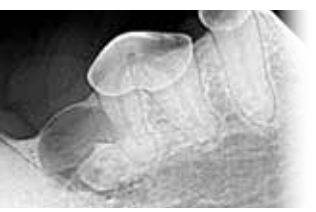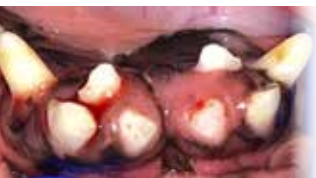STOMATITIS

This term is used for wide spread inflammation of the mucous lining of the structures of the mouth. This is a painful condition that may have a relation to an underlying immune system issue. The gums often appear ulcerated and friable. Most cases require extraction of either all teeth or all teeth behind the canines. If parts of teeth remain, the condition may continue. It is very important to have detailed intraoral imaging to ensure the problem can resolve appropriately.



Dr. Mathis is a leader
in veterinary dentistry
in Des Moines, IA.



EXTRACTIONS

Any time a tooth is damaged, we need to remove that painful tooth or preserve the tooth by another method (such as root canal therapy). There are specific teeth that should be saved if at all possible as these teeth provide structure and function to the mouth: all 4 canine teeth, the upper 4th premolars and lower first molars (large chewing teeth aka carnassial). If teeth are damaged beyond saving, have tooth resorption, or are crowded creating disease, they should be extracted.

DENTIGEROUS CYSTS

Missing teeth that are truly missing are fine, but teeth that appear missing because they are not seen but exist below the gumline are problems. When this tooth does not erupt, the cells continue to try to produce parts of the tooth creating fluid. This happens gradually and the fluid pressure within the jaw causes resorption of the bone around the tooth. The area continues to fill with fluid as the bone gradually resorbs resulting in little to no support until the jaw breaks. All sites of missing teeth need to be verified by intraoral x-rays to see if truly missing. If the cyst (described above), called a dentigerous cyst, has formed, it needs to be removed along with its lining so the cyst does not recur. Many cases have significant bone loss requiring grafts and/or membranes to facilitate appropriate healing.

ENAMEL DEFECTS

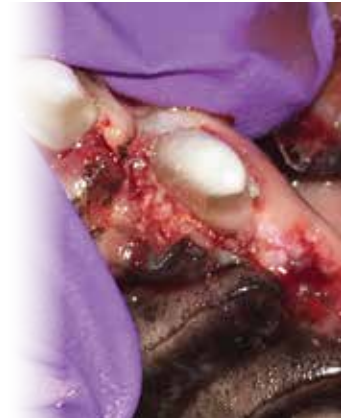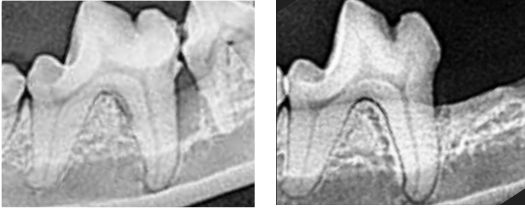
Trauma, drugs, or disease during tooth development can result in abnormal enamel that does not provide good protection to the underlying dentinal tubules eventually resulting in internal disease. Special multi-step products are used to prepare and fill in the defect limiting the damage and improving the cosmetic appearance.

Pets have the same pain as people, though they don't show it in the same manner.



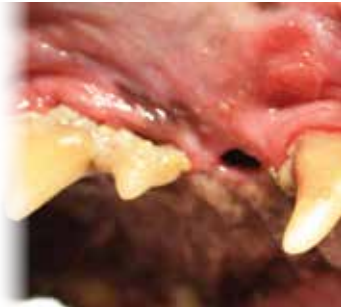GUIDED TISSUE REGENERATION & BONE GRAFTS

Some cases of periodontal disease results in bone loss that still has surrounding and supporting bone. These are areas for which bone grafts and/or special membranes should be used to perform guided tissue regeneration to save a tooth.



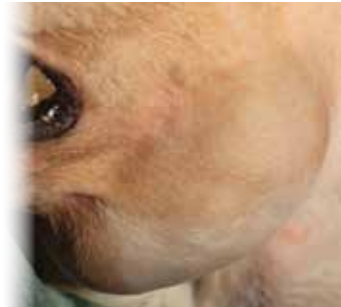SPECIAL FLAPS AND ORAL NASAL FISTULAS

Some types of bone loss around teeth results in the need for flaps to repair the area around the tooth or close the defect in the area of the missing tooth. It is important to treat these correctly or disease will return in as little as two weeks. Some of the major areas we treat are under-erupted lower canines, triangular gingival defects, and oral nasal/antral fistulas (ONF/OAF). ONFs and OAFs are openings between the mouth and the nasal sinuses.

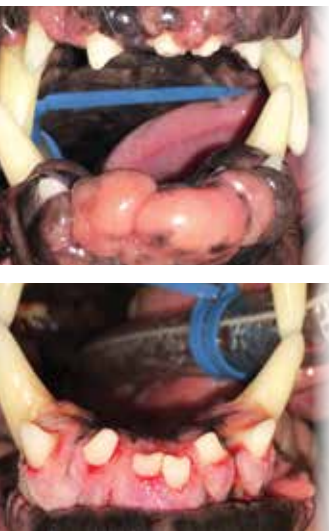


SALIVARY GLAND PROBLEMS

Accumulations of saliva or stones in the salivary ducts can occur due to trauma, foreign material, or infection. Many times these causes are unseen and happen days to weeks earlier than the symptoms. Surgical treatment is needed. A repeat surgery is less successful than an initial surgery.

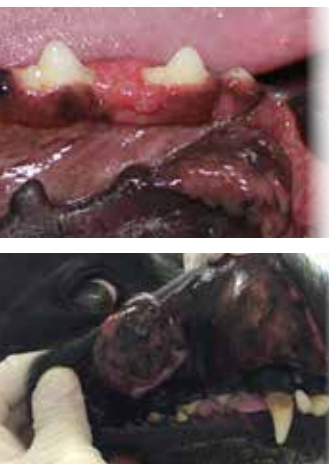

Owners are surprised how the pets' behavior that didn't seem abnormal, is improved and playful once the painful mouth is treated.



GINGIVAL HYPERPLASIA

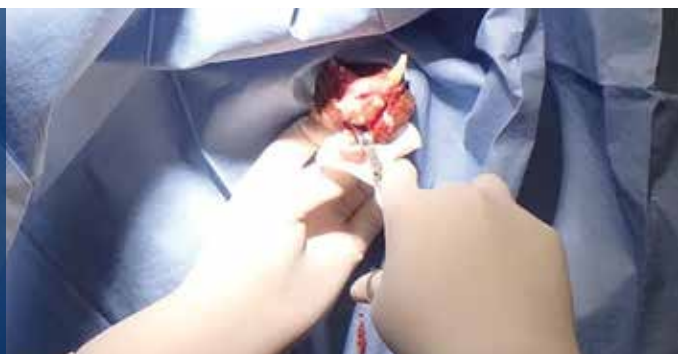Areas of enlarged gum tissue can be present, related to genetics or drug reactions, while other times it is related to oral tumors. In the case of non-tumor causes, the problem is likely called gingival hyperplasia. This creates pockets between the tissue and the tooth trapping food, hair, and debris. The gums need to be resected to normal levels, removing the pocket. In many cases they will re-grow, so follow up is necessary to keep the pet comfortable and prevent tooth loss secondary to periodontal pockets.



ORAL TUMORS

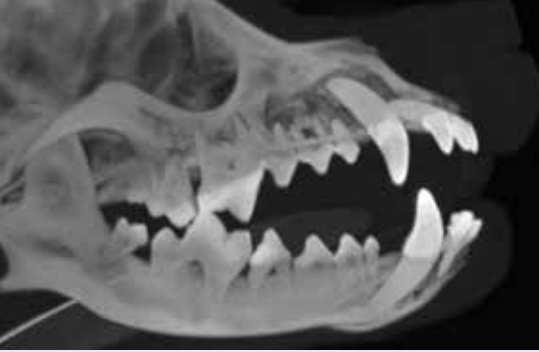Many types of oral tumors exist. Some are benign but locally painful and aggressive. Others are malignant but can still be treated with a high percentage of success. All gum enlargements should be biopsied or resected and submitted to a special oral pathology lab as many similar looking masses can be many different results necessitating different additional therapies. Studies show 32-100% (depends on tumor type) remission with wide margined surgical excisions. Most pets respond well to these major surgeries and live a quality life enjoying further companionship.

Recognizing painful conditions and understanding problem severity can be difficult in an awake pet.



3D IMAGING:

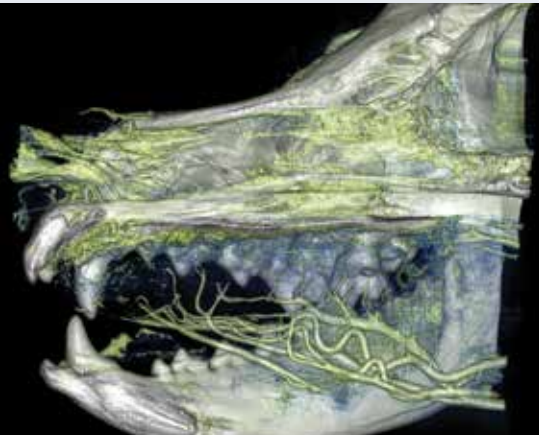
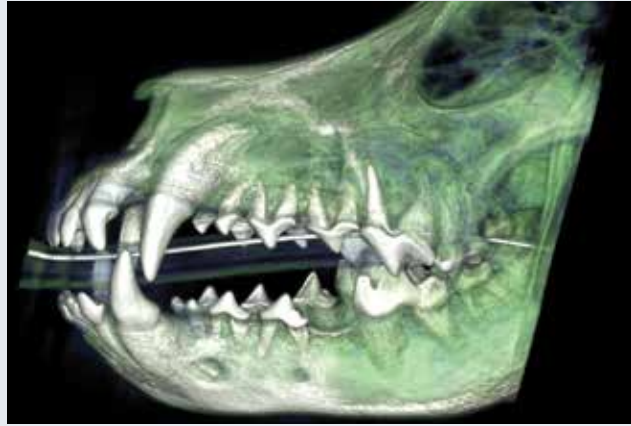4.7 TIMES MORE DIAGNOSTIC THAN INTRAORAL X-RAYS



- Allows full skull views
- Zoom to the root tips to see new detail: as thin as 0.09mm
- Best for trauma/fractures, tumors, ear problems, nasal issues and more
- Great for joint problems and TMJ issues

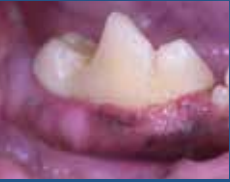3D rotating image view:

- Change the density of the skull to see through to the teeth
- Change the density of specific tissues to better identify tumor margins
- Average scan time is 60% less than full mouth intraoral x-ray sets allowing shorter anesthesia

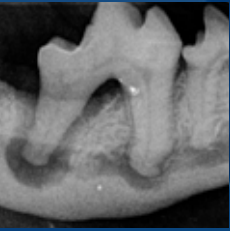


- Contrast can be added to image soft tissues, vessels, tumors, pulp, and much more.
- Perfect for exotic patients
- Best imaging for metastatic lesions
- Cardiac and respiratory fluoroscopy studies with radiology consultation available

72-86% OF PETS HAVE HIDDEN PROBLEMS



What can
be seen
awake



only
seen with
imaging



ANIMAL DENTISTRY
REFERRAL SERVICES

1326 Sunset Drive, Norwalk, IA 50211
www.tooth.vet | www.badbreathisnotnormal.com

CALL US TO SCHEDULE A DENTAL EXAM • 515.421.4VET